Pennsylvania Game Commission Wildlife Disease Reference Library

Fibromas

<u>Other Names</u>: Fibromatosis, rabbit fibromatosis, Shope fibroma, squirrel pox, deer fibroma

Cause

Fibromas are wart-like growths on the skin caused by viruses which are host species specific. Different species of poxviruses cause fibromas in different species of wild and domestic animals. Deer fibromas can be caused by poxviruses, but are more commonly the result of papillomavirus infections. This disease description will focus on fibromas in deer (caused by papillomavirus), rabbits, and squirrels (both caused by poxviruses). For information about poxviruses in birds, refer to the Avian Pox disease description.

Significance

Local poxvirus outbreaks occasionally occur in gray squirrels and cottontail rabbits, but populations do not seem to be negatively affected. Though they can be dramatic when they do occur, fibromas are not a major cause of mortality in deer.

Species Affected

There are many different species of viruses that cause fibromas in an array of wild and domestic animal species. The virus that causes fibromas in squirrels, known as squirrel pox, infects gray and fox squirrels. In eastern cottontail rabbits, the disease is known as rabbit fibromatosis or Shope fibroma. In white-tailed deer and other species of deer, the disease is simply known as deer fibroma. None of these viruses are known to infect humans.

Distribution

Deer fibroma occurs in white-tailed deer and mule deer throughout their range in North America. Squirrel pox has been reported in gray squirrels in Pennsylvania, Maryland, North Carolina, New York, Connecticut, Virginia, Florida, and Michigan. Rabbit fibromatosis infects eastern cottontail rabbits in the eastern and Midwestern United States.

Transmission

In deer the viruses that cause fibromas are probably transmitted primarily through broken skin, though it is not known for certain if this is the only means of transmission. Deer become infected when an area with broken skin comes in direct contact with an infected deer or with a surface that an infected deer rubbed against. Fibromas are more common in bucks, so the virus is probably transmitted during sparring. Biting insects may also be able to transmit deer fibroma.

Squirrel pox; photo courtesy of the Michigan Department of Natural Resources

In squirrels biting insects such as mosquitoes and squirrel fleas are probably the primary mode of transmission. The virus is also easily transmitted from mothers to suckling squirrels.

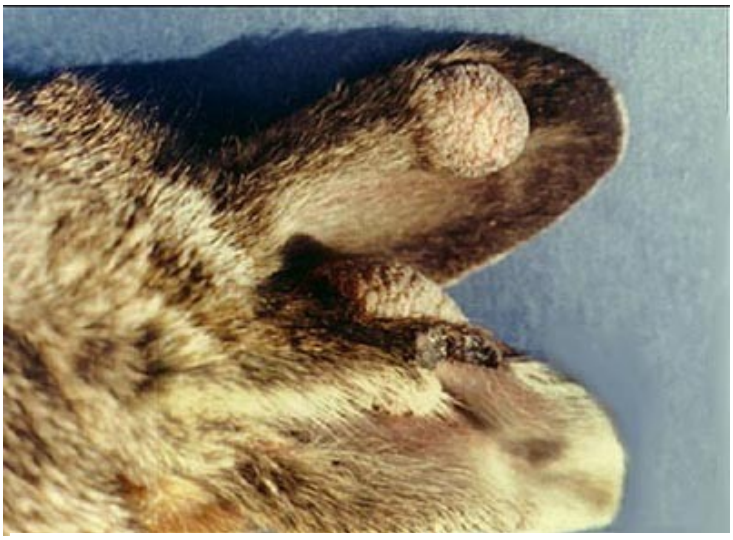

Rabbit fibromatosis; photo courtesy of the Michigan Department of Natural Resources

Rabbit fibroma virus is also most likely transmitted by biting insects such as fleas and mosquitoes.

Clinical Signs

In all species, fibromas are firm, fleshy, wart-like tumors or growths that only involve the skin. For the most part, the overall health of the animal is not affected, and behavior is normal unless the growths interfere with vision, eating, or movement. The growths can occur on any part of the body, and there may be just one or many. In suckling squirrels, fibromas often form around the mouth. Animals with a large fibroma burden or with fibromas that interfere with normal activities may become weak, lose body condition, and sometimes die. In squirrels and rabbits, juveniles are more commonly infected.

Deer with sever fibromas; photo courtesy of the Pennsylvania Game Commission

Diagnosis

Fibromas can often be diagnosed based on visual examination of the growths and

confirmation that only the skin is involved. Microscopic examination of the affected tissue can confirm the diagnosis.

Treatment

There is no effective treatment for fibromas, and in most cases where the affected animal has a normally functioning immune system the tumors will regress naturally. Wildlife rehabilitators may provide supportive care for moderately affected animals, while severely affected animals may need to be euthanized.

Management/Prevention

Fibroma viruses appear to have little impact on populations of wild deer, rabbits, and squirrels, so management is not necessary. The meat of infected animals is safe to eat, because the viruses are confined to the skin and are not known to infect humans. Practices such as supplemental feeding can increase fibroma transmission.

Suggested Reading

Michigan Department of Natural Resources. Wildlife Disease. Deer Fibroma. < http://www.michigan.gov/dnr/1,1607,7-153-10370_12150_12220-26637--,00.html>.

Michigan Department of Natural Resources. Wildlife Disease. Rabbit Fibromatosis. < http://www.michigan.gov/dnr/1,1607,7-153-10370_12150_12220-27256--,00.html>.

Michigan Department of Natural Resources. Wildlife Disease. Squirrel Pox. < http://www.michigan.gov/dnr/1,1607,7-153-10370_12150_12220-27274--,00.html>.

Robinson, A. J., and P. J. Kerr. 2001. Poxvirus Infections. Pages 179-201 *in* E. S. Williams and I. K. Barker, editors. Infectious diseases of wild mammals. Iowa State University Press, Ames, Iowa, USA.

Sundberg, J. P., M. Van Ranst, and A. B. Jenson. 2001. Papillomavirus Infections. Pages 223-231 *in* E. S. Williams and I. K. Barker, editors. Infectious diseases of wild mammals. Iowa State University Press, Ames, Iowa, USA.