Pennsylvania Game Commission Wildlife Disease Reference Library

Blackhead Disease

<u>Other Names</u>: Histomoniasis, infectious enterohepatitis, typhlohepatitis

Cause
Blackhead is a parasitic disease of gallinaceous birds caused by the protozoan named *Histomonas meleagridis*.

Significance
Blackhead occasionally affects wild turkeys, quail, and grouse, but it does not currently have a major impact on wild populations. It was once a significant disease of domestic turkeys, but improved husbandry and biosecurity greatly reduced the number of birds lost due to blackhead.

Species Affected
Blackhead has been reported in several species of gallinaceous (chicken-like) birds including domestic and wild turkeys, domestic chickens, grouse, quail, and pheasants. The wild species most commonly infected in North America are wild turkeys and bobwhite quail. The disease is relatively common in captive raised gamebirds. Blackhead does not infect humans.

Distribution
Blackhead has been known to occur worldwide where chickens, turkeys, and other gallinaceous birds are raised in captivity, though the disease is more common in warmer regions. Most reports of blackhead in wild birds are from North America, though this may be due to lack of information from other parts of the world. Since Pennsylvania stopped farming turkeys for release this disease has ceased to be a problem in wild birds.

Transmission
Histomonas transmission is complicated because the protozoan is carried by another parasite, the common poultry cecal worm (*Heterakis gallinarum*). The *Histomonas* protozoan infects the cecal worm and becomes incorporated into the worm's eggs. This allows the protozoa to be protected from harsh environmental conditions in which it would not normally survive. Both parasites are transmitted when a bird ingests these

eggs. Earthworms can act as an intermediate host for cecal worm larvae that are carrying *Histomonas*. Birds become infected with both parasites when they ingest these infected earthworms. The protozoa cannot survive very long on their own in the environment, but they are shed in the feces of infected birds and can be transmitted to new birds if eaten in a short period of time.

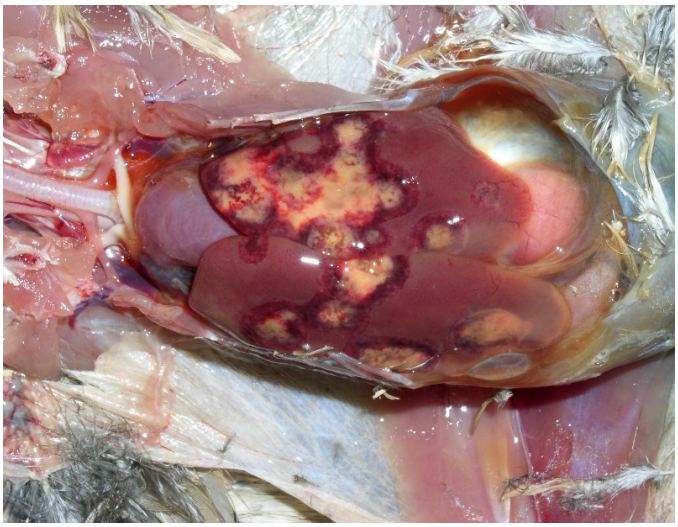

Photos courtesy of PSU Animal Diagnostic Lab

Clinical Signs

Clinical signs usually appear 1-3 weeks following ingestion of the protozoa. Birds infected with blackhead often exhibit non-specific signs such as lethargy, depression, loss of appetite, ruffled feathers, closed eyes, and drooped wings. The feces are often sulfur-yellow in color. The disease is called blackhead because birds will sometimes develop a bluish or blackish coloration of the head, but *this is not a reliable clinical sign*. At necropsy the liver will contain large (0.5 inch or more in diameter) pale gray or yellow circles that are characteristic of blackhead. The ceca are usually thickened, ulcerated, and hemorrhagic.

Some species are more susceptible to blackhead than others. Species such as the domestic chicken and ring-necked pheasant rarely develop clinical disease but readily transmit *Histomonas* as well as the cecal worm. These species act as reservoirs for both parasites and can introduce them to more susceptible species like turkeys.

Diagnosis

Sulfur-yellow colored rings on the liver at necropsy are specific to blackhead; however, they may not be present in all affected birds. When rings are not present on the liver, the disease is diagnosed by laboratory identification of the protozoa. It is a common mistake to confuse other diseases of wild turkeys, such as avian pox, with blackhead. Please refer to the Avian Pox disease description for more information on clinical signs and diagnosis of this disease.

Treatment

Medications are available to treat domestic and captive birds.

Management/Prevention

Proper husbandry and biosecurity are necessary to protect domestic turkeys and captive gamebirds from blackhead. Reservoir species, such as chickens, should not be housed with susceptible species, such as turkeys. Reservoir hosts, such as ring-necked

Suggested Reading

Cole, R. A., and M. Friend. Miscellaneous Parasitic Diseases. Pages 249-258 *in* M. Friend, and J. C. Franson, technical editors. Field Manual of Wildlife Diseases: Birds. United States Geological Survey.

Davidson, W. R. 2008. *Histomonas*. Pages 154-161 *in* C. T. Atkinson, N. J. Thomas, and D. B. Hunter, editors. Parasitic Diseases of Wild Birds. Wiley-Blackwell, Ames, Iowa, USA.

Michigan Department of Natural Resources. Wildlife Disease. Blackhead. < http://www.michigan.gov/dnr/1,1607,7-153-10370_12150_12220-26481--,00.html>.